


# Blindsight and Unconscious Vision: What They Teach Us about the Human Visual System

The Neuroscientist  
2017, Vol. 23(5) 529–541  
© The Author(s) 2016  
Reprints and permissions:  
sagepub.com/journalsPermissions.nav  
DOI: 10.1177/1073858416673817  
journals.sagepub.com/home/nro  


Sara Ajina<sup>1</sup> and Holly Bridge<sup>1</sup>

## Abstract

Damage to the primary visual cortex removes the major input from the eyes to the brain, causing significant visual loss as patients are unable to perceive the side of the world contralateral to the damage. Some patients, however, retain the ability to detect visual information within this blind region; this is known as blindsight. By studying the visual pathways that underlie this residual vision in patients, we can uncover additional aspects of the human visual system that likely contribute to normal visual function but cannot be revealed under physiological conditions. In this review, we discuss the residual abilities and neural activity that have been described in blindsight and the implications of these findings for understanding the intact system.

## Keywords

blindsight, visual system, primary visual cortex, hemianopia, ventral visual stream, dorsal visual stream

## Introduction

The human visual system is a remarkable brain network that allows us to take the light input arriving at the eye and transform it into a colorful, rich experience that comes effortlessly. That this visual percept can remain stable with constant movement of the eyes, across light levels that vary by orders of magnitude and with changing wavelengths of light is mindboggling. The complexity of computation is reflected in the considerable proportion of the human brain (between one-third and one-half) dedicated to processing this visual input (Sereni and Allman 1991). Given the vast quantity of visual information that reaches the brain, it is simply not possible for each and every visual signal to elicit a conscious percept. Conscious vision teaches us about the very important primary visual pathways. However, the somewhat more challenging investigation of non-conscious vision may also reveal properties of less dominant structures and pathways that are still an essential component of the human visual system. This introductory section will lay out the major processing pathways of the human visual system before addressing the consequences of damage to this system, and what we can learn from studying them.

At the retinal level, phototransduction by the rods and cones is the primary source of light sensitive input to the visual system. These signals go through several processing steps within the retinal network before the axons of the

ganglion cells project along the optic nerve. Figure 1A shows the decussation of the optic nerve fibers at the optic chiasm in which the fibers from the temporal retina remain on the ipsilateral side of the brain, whereas those from the nasal retina decussate to form part of the contralateral optic tract. While the figure shows the major geniculostriate projection to the primary visual cortex (V1), there are multiple targets innervated by optic tract fibers, laid out below.

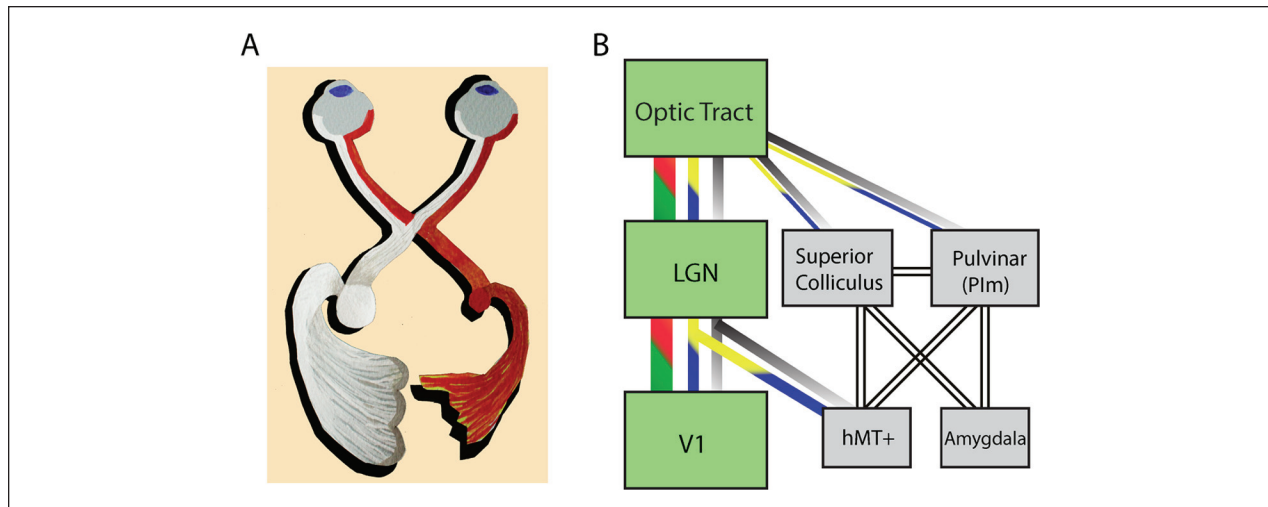
## Pathways Projecting via the Lateral Geniculate Nucleus

In humans and non-human primates, the largest target of the optic tract is the lateral geniculate nucleus (LGN) of the thalamus. While it is now understood that there are likely 15 to 20 types of ganglion cells in the primate retina (Masland 2001) for the purposes of the article, only the 3 major image forming divisions will be addressed. Thus, the LGN receives input from three classes of retinal

<sup>1</sup>Oxford Centre for Functional MRI of the Brain (FMRIB), Nuffield Department of Clinical Neurosciences, University of Oxford, Oxford, UK

## Corresponding Author:

Holly Bridge, Oxford Centre for Functional MRI of the Brain (FMRIB), Nuffield Department of Clinical Neurosciences, University of Oxford, John Radcliffe Hospital, Oxford, OX3 9DU, UK.  
Email: holly.bridge@ndcn.ox.ac.uk



**Figure 1.** (A) The major visual pathway from the eyes to the visual cortex and the reconfiguration at the optic chiasm. The right geniculostriate projection (red) is damaged and hence the lateral geniculate nucleus (LGN) is reduced in size relative to the left intact side (white). (B) Several visual pathways from the optic tract. The major pathway via the LGN to primary visual cortex (V1) is shown in green. The three main classes of retinal ganglion cell are indicated by the red-green (P-cells), gray (M-cells), and blue-yellow (non-M-non-P cells) lines. No assumptions are made about the origins of the connections indicated with the unfilled lines. Illustration in A courtesy of Betina Ip.

ganglion cells: P-cells (midget), M-cell (parasol), and non-M-non-P- (bistratified) cells. The parvocellular layers of the LGN receive predominantly from the P-cells, while the M-cells project to the magnocellular layer. The intralaminar regions, known as the koniocellular layers receive from the non-M-non-P ganglion cells (Fig. 1B). LGN cells from the magnocellular and parvocellular layers project to layers IVC $\alpha$  and IVC $\beta$  of V1, respectively (Hendrickson and others 1978; Hubel and Wiesel 1972), while the koniocellular cells project to superficial layers (Weber and others 1983). This input along the optic radiation provides the greatest subcortical input to V1.

In addition to the LGN projection to V1, there are smaller projections to extrastriate visual areas including V2 (Wong-Riley 1976), V4 (Lysakowski and others 1988) and inferotemporal cortex (Hernandez-Gonzalez and others 1994). However, the LGN connection with extrastriate cortex that has been studied in most depth is that with MT. Sincich and others (2004) were the first to show a direct pathway from the LGN, specifically from the koniocellular neurons to MT (middle temporal area). They proposed that this projection was approximately 10% the size of that from V1 to MT. Furthermore, a study by Jayakumar and others (2013) indicated that when V1 was cooled, thus removing its input to MT, responses in a number of neurons were unaffected. Moreover, this was true for both S-cone isolating stimuli activating the koniocellular pathway and luminance modulated stimuli activating the magnocellular pathway. Such a direct pathway from LGN to MT has also been demonstrated in the marmoset (Warner and others 2010).

### Pathways Projecting via the Pulvinar Nucleus

Adjacent to the LGN, the pulvinar nucleus also plays a role in the relay of visual information, both directly from the optic tract and via the superior colliculus. Direct retinal input is via the M- and non-M-non-P-ganglion cells and targets the inferior pulvinar, shown in both macaque (Covey and others 1994; O'Brien and others 2001) and marmoset (Warner and others 2010; Warner and others 2012) monkeys. These retinorecipient pulvinar neurons then project to area MT, demonstrated using retrograde tracer to identify MT relay cells in Plm (medial portion of the inferior pulvinar nucleus; Warner and others 2010). The pulvinar also shows more diffuse projections to extrastriate visual cortex, including V3d and regions of the ventral stream, predominantly from the lateral nucleus (Kaas and Lyon 2007).

It is estimated that less than 10% of ganglion cells project directly to the superior colliculus and, like the direct pulvinar projections, they are predominantly non-M-non-P-ganglion cells and a few M-ganglion cells (Perry and Covey 1984). Indeed, a recent study in the macaque indicated that the majority of superior colliculus neurons could be activated by S-cone isolating stimuli (Hall and Colby 2014). Projections from the superior colliculus to MT relay via both the inferior pulvinar (posterior and medial divisions; Berman and Wurtz 2010, 2011) and Plm (Lyon and others 2010).

Thus, while the dominant visual pathway projects from the retina to V1 via the LGN, there are a number of alternative pathways to extrastriate cortex via both the LGN and pulvinar that avoid V1.

## A Brief History of Blindsight

It has been known for over a century that damage to the occipital lobe can lead to cortical blindness. Investigations of head injuries sustained during both the Russo-Japanese War of 1904-1905 and World War I by Tatsuji Inouye and Gordon Holmes, respectively, identified the effects of damage to the primary visual cortex (Glickstein and Whitteridge 1987; Holmes 1918; Lister and Holmes 1916). Holmes in particular noted that the location of the cortical damage related to where the patient could not see.

Following on from this discovery, a number of studies reported that V1 damage does not necessarily abolish all visual function in the affected visual field. For example, in the Riddoch syndrome, patients could reliably detect moving stimuli inside their scotoma (Riddoch 1917). In the phenomenon of imaginative completion (“Vorstellungsmässige Ergänzung”), patients with hemianopia could fill-in visual forms across blind sections of the visual field (Poppelreuter 1917). Teuber and colleagues also noted that patients with visual field deficits due to occipital cortex damage appeared to detect information under specific viewing conditions (Teuber and others 1960). Systematic investigation of patients with damage to V1 indicated that they could move their eyes toward visual stimuli presented within the blind regions (Poppel and others 1973), an ability later termed *blindsight* (Weiskrantz and others 1974). Through some extensively studied patients, such as DB and GY, the next 30 years saw the characterisation of visual capacity in the absence of V1. These experiments highlighted the extent of blindsight abilities, including discrimination of orientation and wavelength, in addition to detection of a wide variety of stimuli (reviewed elsewhere by Stoerig 2006). While there were multiple criticisms of the field during this period, the most prominent were those of Campion and others (1983) who suggested that the findings could be explained by light scatter to sighted parts of the visual field or islands of spared calcarine cortex within the hemianopic region. While their other main criticisms have been addressed in detail elsewhere (Cowey 2010), these two issues remain a challenge for the field.

## Insights from Early Functional Neuroimaging

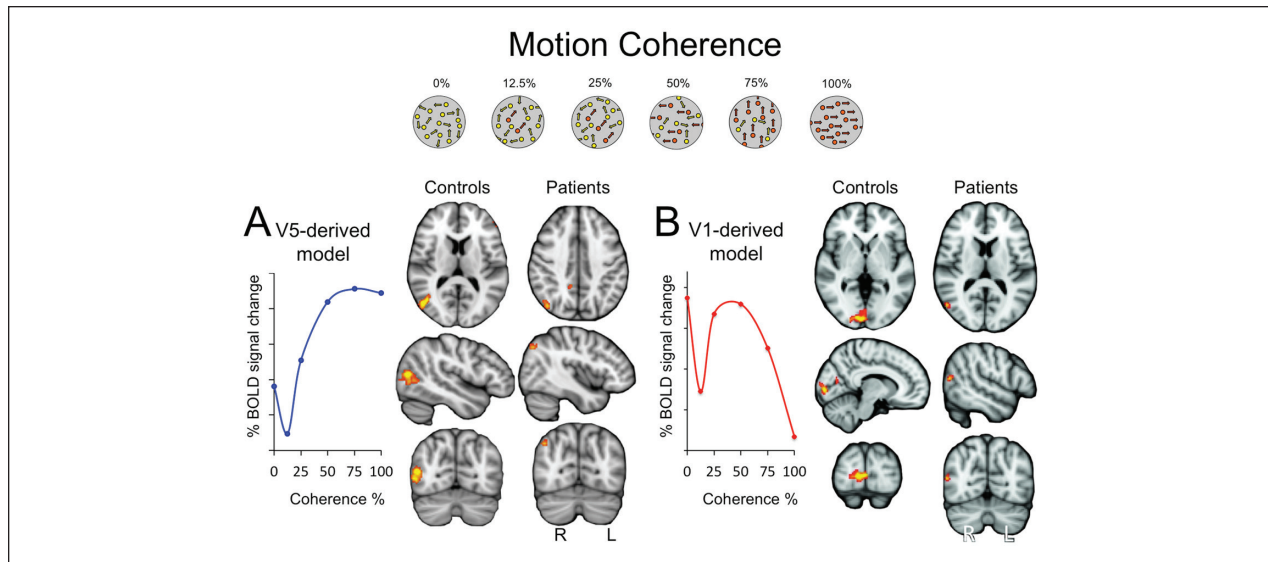
The advent of brain imaging, initially structural magnetic resonance imaging (MRI) and positron emission tomography (PET) but closely followed by functional MRI (fMRI), has allowed visualization of the brain activity that may underlie blindsight and unconscious vision. Having previously relied purely on behavioral measurements that could be considered subjective, Barbur and others (1993) were the first to demonstrate that the motion area hMT+ was activated when patient GY was presented

with a moving stimulus to his blind field. This early study also indicated the potential pitfalls of relying on purely behavioral measurements since their other patient, who also showed blindsight, appeared to activate parts of V1 that were presumably spared tissue. Thus, as described in the previous section, it is impossible to know whether there are islands of V1 remaining in patients without detailed neuroimaging. Morland and others (2004) also raised this issue of spared V1 in a group of patients with hemianopia. Some of this group had damage to lateral regions of extrastriate cortex and showed no evidence of blindsight, whereas two patients were able to discriminate motion direction. While both of these patients showed activity in a region of the lateral occipital lobe corresponding to hMT+, one also showed activity in V1, raising the possibility that this spared cortex could underlie the blindsight abilities.

## The Importance of Motion in Visual Processing

Moving stimuli presented in the blind visual field activate extrastriate visual cortex in hemianopia, specifically ipsilesional human motion area hMT+ (Barbur and others 1993; Bridge and others 2010; Goebel and others 2001; Morland and others 2004; Zeki and Ffytche 1998). Activation in the undamaged hemisphere is also reported (Nelles and others 2002), but is more commonly described in patients with early onset V1 damage (Bridge and others 2008; Leh and others 2006). These findings suggest that there must be non-striate visual input to hMT+ that supports behavioral and neural responses to salient visual motion.

To better understand the nature of this hMT+ activity, our group has recently investigated the pattern by which hMT+ responds to increases in contrast (Ajina and others 2015c) and motion coherence (Ajina and others 2015a). By exploiting two paradigms in which the response pattern in V1 and hMT+ differs in sighted subjects it is possible to determine whether hMT+ in hemianopia and blindsight responds in the same way as in sighted people, where the main input is from V1. The alternative hypothesis is that hMT+ in patients becomes more like V1 because it is now driven predominantly by subcortical input. These motion and contrast paradigms are illustrated in Figures 2 and 3, respectively. In the healthy brain, hMT+ and V1 show different patterns of response to increasing motion coherence. In hMT+, blood oxygenation level-dependent (BOLD) signal change increases with increasing coherence, whilst signal in V1 decreases at high levels of coherence (shown schematically in the model, Figure 2). In hemianopic patients, the hMT+ response in the damaged hemisphere resembles that of



**Figure 2.** In the healthy visual system hMT+ and V1 show distinct response patterns to increasing the proportion of coherent motion. (A) In hMT+, blood oxygenation level-dependent (BOLD) signal change increases with increasing coherence, apart from an initial dip. A model describing this pattern shows a clear correlation with hMT+ activity in controls. In contrast, in patients with visual field loss due to V1 damage who are shown images inside their scotoma, hMT+ has no significant correlation with this control-derived model. (B) V1 in healthy controls shows a decrease in response to increasing motion coherence. When a model of this V1 pattern is generated, unsurprisingly, in control subjects V1 has a response significantly correlated to this pattern. However, in the blind field of patients, the only cortical area that shows this V1-like response is hMT+ (from Ajina and others 2015a).

V1, rather than hMT+, and shows a significant correlation with the V1 model. Similarly, with luminance contrast, V1 normally shows a linear increase in response to increasing contrast (Figure 3). The response in healthy hMT+ saturates at low contrast, reflected in a more logarithmic pattern of activation. In the damaged hemisphere of hemianopic patients the response in hMT+ is linear and no occipital regions show any logarithmic responses. Thus, together these two experiments support the idea that the response pattern of hMT+ is changed qualitatively after V1 damage to become more similar to low-level visual cortex, perhaps because its dominant input is now subcortical.

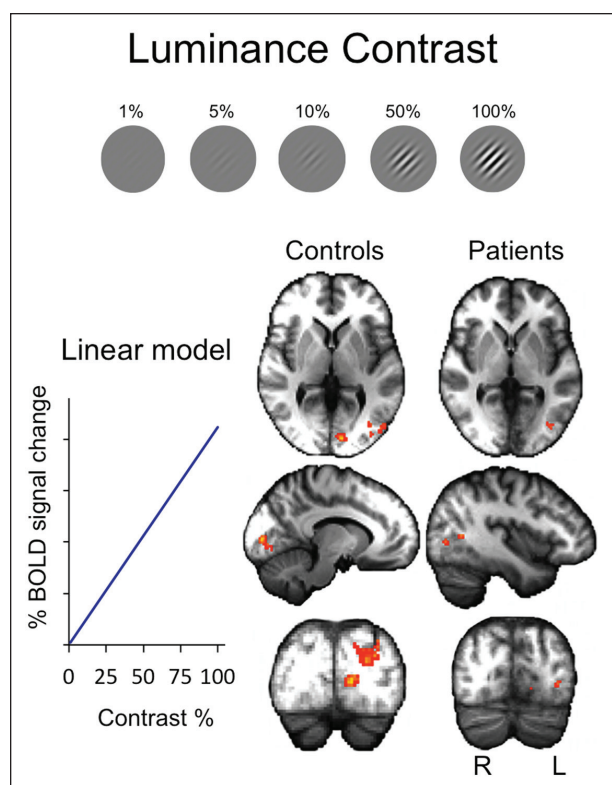
A complementary approach to fMRI, diffusion MRI, and particularly tractography, has proven useful to investigate the anatomical pathways underlying blindsight. Both GY and a patient with bilateral striate cortex damage and motion blindsight show intact ipsilateral connections between LGN and hMT+ in the damaged hemisphere(s) (Bridge and others 2010; 2008). Furthermore, GY, who sustained brain damage aged 8 years, also demonstrates increased callosal connections between hMT+ bilaterally, as well as an unusual crossing pathway with LGN in the undamaged hemisphere (Bridge and others 2008). Leh and others (2006) tested four hemispherectomy patients who sustained structural brain damage at birth or in early childhood. Two patients showed attentional blindsight

according to a spatial summation paradigm. While responses to motion were not specifically addressed, they adopted an open approach to tractography that measured all connections involving the superior colliculus. They found that only patients with blindsight showed crossing tracts between the superior colliculus in the damaged hemisphere and regions of the intact hemisphere, as well as strong ipsilateral connections in the damaged hemisphere.

The variability amongst naturally occurring human V1 lesions has been cited as a limitation of human research (Schmid and others 2009), particularly when interpreting individual case studies. However, heterogeneity in the precise location of structural damage can prove useful when patients are categorized according to their residual visual performance. By determining which connections are consistent in patients with or without blindsight, it may be possible to identify the structures and pathways underlying blindsight abilities.

Our recent tractography study employed this strategy in seventeen patients with primary visual cortex damage sustained in adulthood (Ajina and others 2015b). Patients were categorized as blindsight positive or negative according to performance on a 2AFC (two-alternative forced-choice) detection paradigm. All 12 blindsight positive patients showed intact geniculo-hMT+ connections, while this pathway was either impaired or not measurable





**Figure 3.** V1 shows a linear response to increasing stimulus contrast in healthy control subjects. hMT+ shows this pattern in the damaged hemisphere of hemianopic patients, and to some extent in healthy controls. However, the strongest response in healthy hMT+ is to a logarithmic model, a pattern not seen in hemianopic patients (from Ajina and others 2015c).

in the 5 blindsight-negative patients. Conversely, an intact connection between hMT+ and the superior colliculus, or hMT+ bilaterally could not account for all blindsight positive cases and was present in some patients without blindsight (see Fig. 4). This suggests that an ipsilesional connection between LGN and hMT+ is critical for this type of blindsight in patients with adult onset pathology.

Overall, the study of motion in blindsight has revealed a great deal about the visual system. First, we have learnt that V1 is not necessary for behavioral responses to visual motion, which can even extend to direction discrimination. Similarly, neural responses to motion in the extrastriate cortex can occur independently of V1, as evidenced by the neuroimaging of patients with postchiasmal damage. Second, we have learnt that V1 is required for normal motion coherence and contrast responses in hMT+. However, these “characteristic” responses cannot be intrinsic to MT neurons since hMT+ in the same damaged hemisphere shows a normal response to ipsilateral stimulation of the sighted field. Third, work in this field

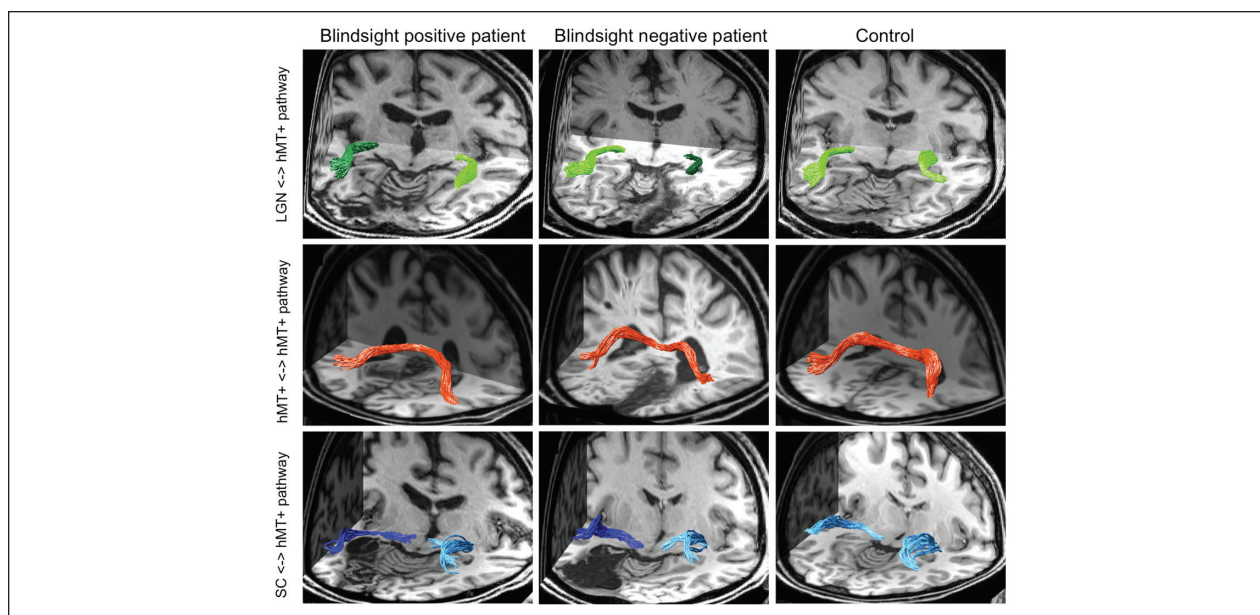
suggests that direct subcortical connections to hMT+ are probably inherent to all of us; we simply cannot normally isolate their physiological properties or contribution to normal neural activity. Patients with damage to V1 allow us to reveal these properties and relate them to residual visual function. Last, a geniculate-hMT+ pathway appears specifically to be involved in 2AFC motion blindsight, while additional interhemispheric pathways may be important in juvenile cases.

## Unconscious Processing of Shape and Form Are Notoriously Hard

Historically, patients with postgeniculate visual pathway damage perform very poorly in tests of shape discrimination (Blythe and others 1987) and this remains a relatively under investigated area of blindsight. The low-level features of stimuli such as color and orientation appear to influence behavior in the absence of conscious perception, and are also demonstrable in tests of unconscious vision in healthy participants (Boyer and others 2005; Schoenfeld and others 2002; Weiskrantz 1987). While higher level attributes such as face shape, identity adaptation, and word meaning seem to be contingent on conscious access (Kang and others 2011; Stein and Sterzer 2011), there are also cases of unconscious perception of words.

There are, in fact, examples of successful shape discrimination in patients with blindsight (Dineen and Keating 1981; Marcel 1998; Pasik and others 1969), although the neural activity associated with unconscious visual stimulation of the ventral stream is notably weaker than equivalent paradigms aimed at stimulating the dorsal stream, both in blindsight and non-conscious masked healthy vision (Baseler and others 1999; Lin and He 2009).

Some patients with blindsight improve their ability to make discriminations over time. GY became able to match blind field stimuli to a selection of images in his sighted field with a remarkably high degree of precision (Morland and others 1999; Stoerig and Barth 2001). He could also perform gender identification for faces in his blind field (Morris and others 2001), as could another patient described more recently (Solca and others 2015). Patient DB, who lacked awareness in his blind field, demonstrated considerable improvement in form discrimination, including identification of low-contrast achromatic outlines of Snodgrass images after being told the stimulus category (Trevethan and others 2007). Petra Stoerig has also described a patient with posterior circulation stroke who developed ipsilesional ventral fMRI responses to color after a year of weekly visual testing (Stoerig 2006). This suggests that ventral regions of extrastriate cortex can receive visual input in the absence of V1—perhaps direct diffuse pulvinar projections or via interhemispheric callosal connections (Van Essen and others 1982).



**Figure 4.** Diffusion tractography illustrating three visual pathways in patients with blindsight (blindsight positive), without blindsight (blindsight negative), and healthy controls. In blindsight-positive patients, only the lateral geniculate nucleus (LGN)–hMT+ pathway showed consistently intact microstructure, suggesting this may be the route underlying any residual visual function (from Ajina and others 2015b).

Identifying suitable patients for neuroimaging studies can be challenging; we also cannot be certain that blindsight is not an adaptive response to neural damage. In unconscious healthy vision, one can investigate neural responses to unconscious visual stimuli with relative ease. Early studies found neural activity to be virtually eliminated in the ventral stream during interocular suppression using binocular rivalry (Fang and He 2005; Pasley and others 2004; Sheinberg and Logothetis 1997; Tong and others 1998). However, more recent work has revealed weak category-specific responses, for example, to invisible faces in face-sensitive ventral cortex (Jiang and He 2006), or to suppressed faces or houses (Sterzer and others 2008). This is supported by equivalent electro- and magnetoencephalographic measurements (Jiang and others 2009; Sterzer and others 2009) and suggests that unconscious ventral processing may be more significant than first considered. This assertion may also extend to patients with visual cortex damage.

In summary, these studies have taught us that the processing of shape and form is more closely tied to V1 and our conscious visual experience than visual motion. Nevertheless, there is increasing evidence that certain higher level features can be processed independently of V1 and in the absence of conscious perception. The relative weakness of ventral cortex activity may simply mean it is more challenging to detect in neuroimaging studies. Similarly, if a certain threshold of activity is required for significant behavioral responses, it may not be surprising

that this type of blindsight is more difficult to demonstrate. Perhaps the most intriguing observation is that unconscious responses can evolve over time or with training after V1 damage. This suggests that the underlying pathway can support visually guided behavior, and that neuroplastic changes may facilitate behavioral responses.

### Guidance of the Motor System Can Be Driven in the Absence of V1

The previous section considered unconscious processing in the ventral visual stream, both in the healthy visual system and in blindsight. Goodale and Milner (1992) introduced the idea of vision for perception in the ventral stream and vision for action in the dorsal stream. This division, based predominantly on patients with cortical damage, is an excellent example of what can be learnt about the human visual system from studying disorders. Almost by definition, much processing in the dorsal stream can be unconscious; patient DF who has bilateral damage to the lateral occipital cortex can accurately grasp objects that she cannot perceive.

The ability of hemianopic patients to locate targets, either by saccades or pointing, was one of the first indications of blindsight, and this type of motor response has been termed *action blindsight* (Danckert and Rossetti 2005). Since the role of action blindsight has been reviewed rather extensively, here we just consider what it

can teach us about the intact visual system. Whitwell and others (2011) determined that while a hemianopic patient was able to accurately scale grip to objects presented in the blind field, the patient could not perform this task when a delay was inserted after presentation of the stimulus. This suggests that “real-time” perception for action has a different mechanism than memory for object size, which appears to require V1, a finding supported by fMRI in healthy individuals (Singhal and others 2013).

An extreme example of action blindsight is the navigation that has been described in the bilaterally hemianopic patient TN. de Gelder and others (2008) demonstrated that TN was able to navigate along a corridor avoiding obstacles, despite being unable to see. This type of experiment is not possible in those with unilateral damage, so data are sparse, but it does suggest the motor system has access to visual information that is not consciously perceived. A pathway underlying such information flow will likely include the posterior parietal cortices which are involved in the visual guidance of movement (reviewed in Culham and others 2006).

While much understanding of the dorsal visual stream has emerged from the study of patients with extrastriate cortical lesions, blindsight has started to contribute additional knowledge. Specifically, that there is a pathway to the parietal cortex involved in guiding movement that avoids V1. Furthermore, this pathway is only sufficient for guidance while visual information is present, not when recall is required.

## Visual Processing in the Two Hemispheres Is Inherently Interlinked

In normal motion processing, activation of hMT+ in both hemispheres is highly correlated, even though ipsilateral responses tend to be weaker (Tootell and others 1988). Bilateral responses are also common in the ventral stream, and are particularly well described for category-specific processing, including parahippocampal responses to objects or places compared with faces (Epstein and Kanwisher 1998), and FFA responses to faces or scrambled controls (Farah 1990; Kanwisher and others 1997). Lateralization of activity, in particular to the right hemisphere when viewing faces, is not uncommon, although its predominance tends to vary amongst individuals (Kanwisher and others 1997).

There are a number of examples in blindsight research that indicate the importance of interhemispheric connections. As already mentioned, early tractography studies suggested that blindsight patients who sustained brain damage relatively early in life showed enhanced interhemispheric connectivity (Bridge and others 2008; Leh and others 2006). Furthermore, a transcranial magnetic

stimulation study in patient GY found that he was able to perceive visual sensations of phosphenes in his blind field, but only if stimulation was applied bilaterally over hMT+, and not if stimulation was restricted to ipsilesional hMT+ (Silvanto and others 2007). These findings are consistent with the observation of Keshavan and others (2002) that the corpus callosum shows an increased propensity for plasticity, and continues to grow in cross-sectional area until early adulthood.

Research into rehabilitation after visual cortex damage also suggests that the intact, ipsilateral hemisphere may become involved in the recovery of visually evoked responses. Nelles and others (2009) trained stroke patients on a visual search task for 4 weeks and observed an increase in contralesional extrastriate activity during blind hemifield stimulation post-training.

Despite the potential for the ipsilateral hemisphere to increase activation, it has also been suggested that the “intact” visual field can demonstrate deficits in visual performance, so-called sight-blindness (Bola and others 2013; Cavérian and others 2015). Contrast sensitivity (Hess and Pointer 1989) and more complex visual tasks, such as perceptual grouping (Schadow and others 2009) have been implicated. One explanation is that interhemispheric transfer has been impaired (Rizzo and Robin 1996). There is also likely to be a global effect on the entire visual field, since ipsilesional field deficits do not retinotopically match the blind field loss (Bola and others 2013).

Taken together, these studies suggest that interhemispheric connections and an involvement of the undamaged hemisphere may be important for plasticity in the visual brain. The rehabilitation of visual field loss is notoriously difficult following a stroke or brain injury (eg, see Ajina and Kennard 2012), and is often considered to be permanent after 3 to 6 months (Zhang and others 2006). If researchers can explore these hypotheses further, perhaps we will be able to not only develop more effective rehabilitation tools for the future but also understand the seamless binding of the two visual fields in the healthy visual system.

## Affective Pathways Revealed by Studies of Blindsight and Unconscious Vision

Our unconscious response to emotional stimuli probably reflects an evolutionary mechanism, designed to protect us from dangerous or threatening situations. Extensive work over the last few decades has explored how this may occur, and whether there may be a “quick and dirty” pathway to facilitate it (see Celeghin and others 2015 for a more detailed review). Overwhelmingly, studies have shown that the amygdala is involved in emotional processing, both in conscious and unconscious conditions (Adolphs



and others 2005). There is also considerable support for a connection and/or interaction between the amygdala, the pulvinar nucleus of the thalamus, and the superior colliculus in unconscious processing (Liddell and others 2005; Morris and others 1996).

Patient GY is able to successfully discriminate different facial expressions in his blind field from videos of a female face (de Gelder and others 1999) and shows increased bilateral (Morris and others 2001) or unilateral right amygdala activity (de Gelder and others 2005) for fearful faces in his blind hemifield. He has also demonstrated bilateral superior colliculus, pulvinar, amygdala, and right fusiform gyrus activity for angry versus neutral whole-body actions (Van den Stock and others 2011).

Even in bilateral cortical blindness, patient TN can discriminate positive or negative facial expressions inside his scotoma (Pegna and others 2005). Furthermore, TN's right amygdala exhibits activity in response to faces depicting anger, happiness or fear compared with neutral expressions, with fear eliciting the strongest effect.

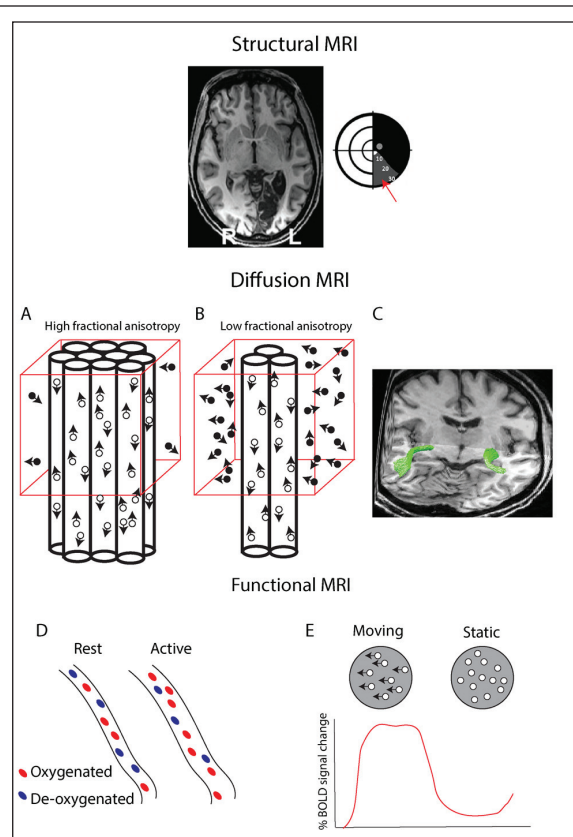
This collection of work strongly supports a role for the amygdala in unconscious processing of emotion and implicates additional structures, such as the superior colliculus and pulvinar (de Gelder and others 2005; Van den Stock and others 2011). This raises the possibility of a specific subcortical pathway that might underlie affective blindsight. In patient GY, Tamietto and others (2012) used diffusion MRI to identify a connection between the pulvinar and amygdala, and between superior colliculus and amygdala via the pulvinar in controls as well as GY. Compared to controls, GY showed a significantly greater number of streamlines in his damaged hemisphere for these pathways, as well as increased fractional anisotropy in connections between the pulvinar and amygdala (see Box 1 for explanation). These pathways may be important for affective blindsight, and future work could determine whether such postulated neuroplastic changes are specific to patients with blindsight or a generalized response to unilateral visual cortex damage.

**Box 1.** Applying Magnetic Resonance Imaging (MRI) to the Study of Blindsight.

Structural MRI can provide detailed information about the structure of the brain, particularly the presence or absence of spared islands of V1 cortex. This becomes important when determining whether or not patients have blindsight or residual vision. T1-weighted structural images can also provide information about the size of the lesion and the extent to which it affects surrounding white matter. In the figure, the example shows a large lesion to the left occipital lobe that encompasses the entire medial bank. However, the Humphrey perimetry, shown schematically indicates that there is some residual vision in the lower visual field (gray region indicated by

(continued)

**Box 1. (continued)**



the red arrow). It is then possible to examine the MRI image to determine whether there is residual V1 tissue in the corresponding dorsal region.

Diffusion MRI exploits the diffusion properties of water molecules to allow the reconstruction of white matter tracts within the visual system. The figure shows that water molecules within axonal bundles (open circles) have a restricted direction of movement compared with those in fluid and gray matter (black circles). Within a given voxel (red box), the proportion of water molecules within axon bundles will determine how anisotropic the diffusion signal is. In (A), the majority of water molecules are within axons and therefore the voxel will have a strong directionality (or fractional anisotropy, FA). In contrast, if there is degeneration within a particular axonal bundle, fewer water molecules will have constrained movement and therefore the FA will be lower (B). The directionality of particular bundles can then be used to compare tracts running between specific structures in patients and control subjects. C shows an example of tracts between LGN and HMT+ in a healthy subject (green).

Functional MRI allows measurement of the activity of different brain regions. The blood oxygenation level-dependent (BOLD) signal relies on the differing magnetic properties of oxygenated and deoxygenated hemoglobin. When a region of the brain becomes active, there is an increased flow of oxygenated hemoglobin to the specific region of high neuronal

(continued)



**Box 1. (continued)**

activity. This leads to a change in the ratio of oxygenated and deoxygenated hemoglobin that can be detected by the MRI scanner (shown in D). The change in signal between two different conditions can be quantified as a percentage signal change and used to calculate the strength of a given response (E), for example, in hMT+ to moving dots.

In unconscious healthy vision, a variety of techniques can be used to render emotionally salient images invisible, including very rapid stimulus presentations, backward masking, binocular rivalry, and continuous flash suppression. Similar to blindsight, neuroimaging studies have revealed that fearful faces stimulate the amygdala bilaterally during visible and invisible conditions, although activation for invisible emotionally neutral faces is much weaker (Jiang and He 2006; Williams and others 2004). In some cases, this is interpreted as an illustration of “automatic” processing in which the amygdala responds to early, crude representations of emotionally salient stimuli. In fact, this is a somewhat complicated area that remains a subject of debate. While the full discussion is beyond the scope of this article, one school of thought is that the processing of affective visual stimuli is in fact no faster than cortical processing of visual stimuli in general (Pessoa and Adolphs 2010). Conversely, there is increasing evidence for more rapid amygdala processing of fearful facial expressions (Mendez-Bertolo and others 2016). There are also examples of unconscious affective processing in patients with bilateral amygdala lesions, which suggests that the amygdala alone may not be critical for this response (Tsuchiya and others 2009), and that earlier models of affective pathways may have been overly simplistic.

The most recent studies in this field focus on social and contextual stimulus cues, which can both be processed unconsciously (Gobbini and others 2013; Ruderman and Lamy 2012) and activate the amygdala (Frith and Frith 2012). It appears now that even stimulus category (eg, animal or object) can influence the degree of amygdala activation for relatively matched affective unconscious stimuli (Fang and others 2016). Overall, this suggests that there may be a shift in consensus for the mechanism underlying unconscious affective processing. Perhaps this is a more complex visual system that considers the context of unconscious emotionally valent stimuli via early cortical interactions (Pessoa and Adolphs 2010; Troiani and Schultz 2013).

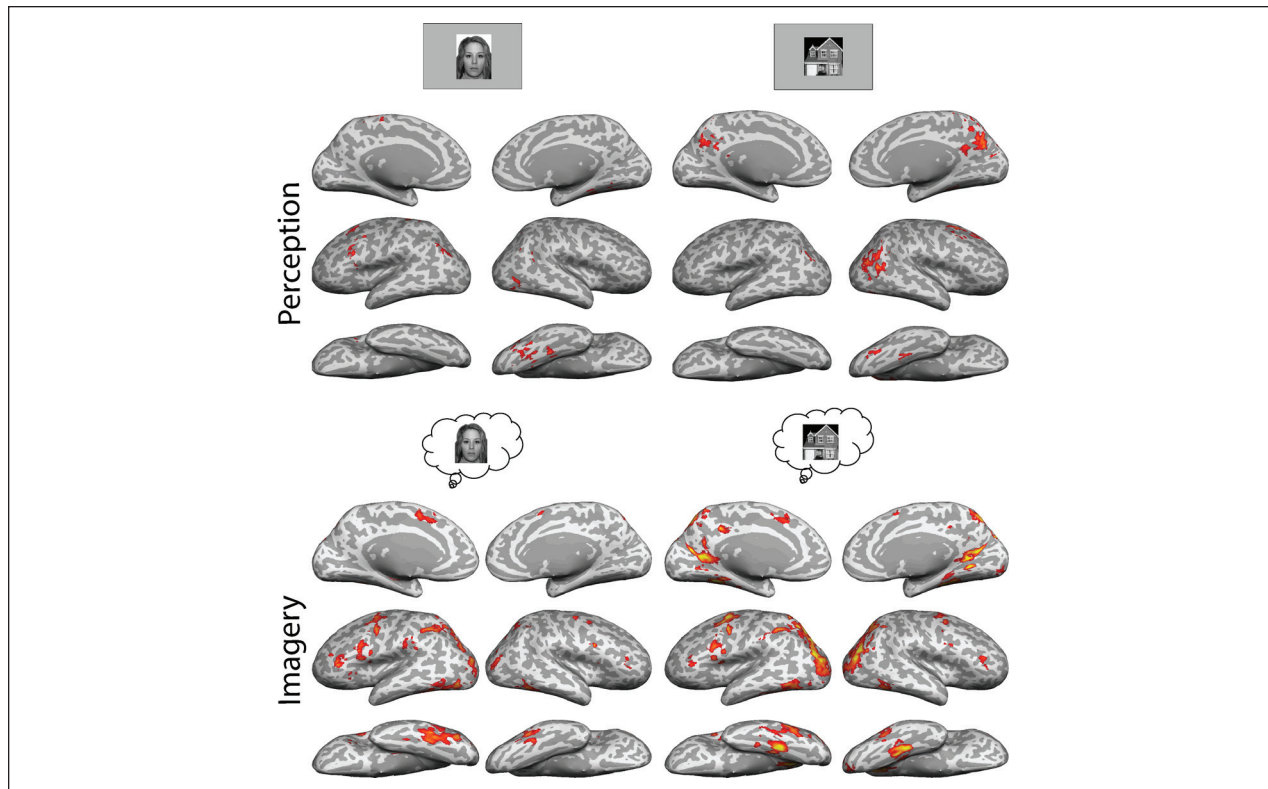
### **Visual Mental Imagery Can Be Investigated in Bilateral Visual Cortical Damage**

Visual mental imagery is the ability to produce a visual percept without any stimulation of the retina. This is

most evident during dreaming, but these mental images can also be produced voluntarily by most individuals. The extent to which people can visualize images has been quantified using the Vividness of Visual Imagery Questionnaire (VVIQ; Marks 1973) and there is considerable variability across the population, including a group who are unable to generate images, recently termed *aphantasia* (Zeman and others 2015). One of the major questions regarding visual imagery is the role of V1, since no perceptual input from the retina is required to form these images. This question has been contentious for a considerable period, with equal numbers of studies suggesting a critical role for V1 as those indicating it not being necessary, reviewed by Pearson and others (2015). Patients with bilateral damage to V1 offer the opportunity to first ask whether visual mental imagery is preserved (indicating that V1 is not necessary) and second, if so, whether the neural processing is comparable to sighted subjects. In patient SBR, who has damage restricted to V1 bilaterally, Bridge and others show preserved visual imagery using the VVIQ and with the pattern of activation to imagery of faces and houses (Bridge and others 2012). While presentation of face and house stimuli evoke little activation in the fusiform face area and parahippocampal place area respectively, there is considerably more activity in these areas during mental imagery. This comparison is illustrated in Figure 5. A later study described patient TN who has complete destruction of V1 bilaterally and some surrounding areas (de Gelder and others 2015). Despite this extensive damage, TN reported being able to generate visual images and showed neural activation patterns comparable to those of controls. Thus, the use of these two patients with blindsight has also indicated that V1 is not required for visual mental imagery.

### **Concluding Comments**

Blindsight has been studied for more than 40 years and has faced many challenges, from spared cortex and scattered light to heterogeneity of damage and awareness. The use of MRI to objectively measure neural responses to be used in tandem with behavioral responses has helped address some of the key challenges. Moreover, the use of larger groups of patients rather than case studies has started to allow the correlation of behavior to a number of measures of brain structure and function. This should not only reveal the pathways critical to blindsight but also illustrate the pathways that may provide additional visual input in the healthy visual system. Furthermore, by attempting to strengthen residual pathways through rehabilitation in blindsight, we may understand the potential for



**Figure 5.** Cortical responses in bilaterally hemianopic patient SBR. When presented with images of faces and houses, he shows very little occipital activation, with small signals in the fusiform and parahippocampal places areas respectively (upper row). In contrast, when generating images of faces and houses, there is extensive activation throughout the occipital and posterior parietal lobes. This indicates that while VI is critical for perceiving such stimuli, it is not necessary for visual mental imagery (from Bridge and others 2012).

neuroplasticity within the visual system and how it compares to other neural systems.

### Acknowledgments

The authors would like to thank Marco Tamietto, Betina Ip, Ivan Alvarez, and Stephanie Larcombe for constructive comments on the manuscript.

### Declaration of Conflicting Interests

The author(s) declared no potential conflicts of interest with respect to the research, authorship, and/or publication of this article.

### Funding

The author(s) disclosed receipt of the following financial support for the research, authorship, and/or publication of this article: Sara Ajina was funded by a Wellcome Trust Clinical Training fellowship, a Goodger and Schorstein Scholarship from the University of Oxford and the Oxford Biomedical Research Centre. Holly Bridge is a Royal Society University Research Fellow.

### References

- Adolphs R, Tranel D, Buchanan TW. 2005. Amygdala damage impairs emotional memory for gist but not details of complex stimuli. *Nat Neurosci* 8(4):512–8.
- Ajina S, Kennard C. 2012. Rehabilitation of damage to the visual brain. *Rev Neurol (Paris)* 168(10):754–61.
- Ajina S, Kennard C, Rees G, Bridge H. 2015a. Motion area V5/MT+ response to global motion in the absence of V1 resembles early visual cortex. *Brain* 138(1):164–78.
- Ajina S, Pestilli F, Rokem A, Kennard C, Bridge H. 2015b. Human blindsight is mediated by an intact geniculocortical pathway. *Elife* 4:e08935. doi:10.7554/eLife.08935.
- Ajina S, Rees G, Kennard C, Bridge H. 2015c. Abnormal contrast responses in the extrastriate cortex of blindsight patients. *J Neurosci* 35(21):8201–13.
- Barbur JL, Watson JD, Frackowiak RS, Zeki S. 1993. Conscious perception without V1. *Brain* 116 (pt 6):1293–302.
- Baseler HA, Morland AB, Wandell BA. 1999. Topographic organization of human visual areas in the absence of input from primary cortex. *J Neurosci* 19(7):2619–27.
- Berman RA, Wurtz RH. 2010. Functional identification of a pulvinar path from superior colliculus to cortical area MT. *J Neurosci* 30(18):6342–54.

- Berman RA, Wurtz RH. 2011. Signals conveyed in the pulvinar pathway from superior colliculus to cortical area MT. *J Neurosci* 31(2):373–84.
- Blythe IM, Kennard C, Ruddock KH. 1987. Residual vision in patients with retrogeniculate lesions of the visual pathways. *Brain* 110(pt 4):887–905.
- Bola M, Gall C, Sabel BA. 2013. The second face of blindness: processing speed deficits in the intact visual field after pre- and post-chiasmatic lesions. *PLoS One* 8(5):e63700.
- Boyer JL, Harrison S, Ro T. 2005. Unconscious processing of orientation and color without primary visual cortex. *Proc Natl Acad Sci U S A* 102(46):16875–9.
- Bridge H, Harrold S, Holmes EA, Stokes M, Kennard C. 2012. Vivid visual mental imagery in the absence of the primary visual cortex. *J Neurol* 259(6):1062–70.
- Bridge H, Hicks SL, Xie J, Okell TW, Mannan S, Alexander I, and others. 2010. Visual activation of extra-striate cortex in the absence of V1 activation. *Neuropsychologia* 48(14):4148–54.
- Bridge H, Thomas O, Jbabdi S, Cowey A. 2008. Changes in connectivity after visual cortical brain damage underlie altered visual function. *Brain* 131(pt 6):1433–1444.
- Campion J, Latto R, Smith YM. 1983. Is blindsight an effect of scattered-light, spared cortex, and near-threshold vision. *Behav Brain Sci* 6(3):423–47.
- Cavézian C, Perez C, Peyrin C, Gaudry I, Obadia M, Gout O, and others. 2015. Hemisphere-dependent ipsilesional deficits in hemianopia: sightblindness in the ‘intact’ visual field. *Cortex* 69:166–74.
- Celeghin A, de Gelder B, Tamietto M. 2015. From affective blindsight to emotional consciousness. *Conscious Cogn* 36:414–25.
- Cowey A. 2010. The blindsight saga. *Exp Brain Res* 200(1):3–24.
- Cowey A, Stoerig P, Bannister M. 1994. Retinal ganglion cells labelled from the pulvinar nucleus in macaque monkeys. *Neuroscience* 61(3):691–705.
- Culham JC, Cavina-Pratesi C, Singhal A. 2006. The role of parietal cortex in visuomotor control: what have we learned from neuroimaging? *Neuropsychologia* 44(13):2668–84.
- Danckert J, Rossetti Y. 2005. Blindsight in action: what can the different sub-types of blindsight tell us about the control of visually guided actions? *Neurosci Biobehav Rev* 29(7):1035–46.
- de Gelder B, Morris JS, Dolan RJ. 2005. Unconscious fear influences emotional awareness of faces and voices. *Proc Natl Acad Sci U S A* 102(51):18682–7.
- de Gelder B, Tamietto M, Pegna AJ, Van den Stock J. 2015. Visual imagery influences brain responses to visual stimulation in bilateral cortical blindness. *Cortex* 72:15–26.
- de Gelder B, Tamietto M, van Boxtel G, Goebel R, Sahraie A, van den Stock J, and others. 2008. Intact navigation skills after bilateral loss of striate cortex. *Curr Biol* 18(24):R1128–9.
- de Gelder B, Vroomen J, Pourtois G, Weiskrantz L. 1999. Non-conscious recognition of affect in the absence of striate cortex. *Neuroreport* 10(18):3759–63.
- Dineen J, Keating EG. 1981. The primate visual system after bilateral removal of striate cortex. Survival of complex pattern vision. *Exp Brain Res* 41(3–4):338–45.
- Epstein RA, Kanwisher N. 1998. A cortical representation of the local visual environment. *Nature* 392(6676):598–601.
- Fang F, He S. 2005. Cortical responses to invisible objects in the human dorsal and ventral pathways. *Nat Neurosci* 8(10):1380–5.
- Fang Z, Li H, Chen G, Yang J. 2016. Unconscious processing of negative animals and objects: role of the amygdala revealed by fMRI. *Front Hum Neurosci* 10:146.
- Farah M. 1990. Visual agnosias. Cambridge, MA: MIT Press.
- Frith CD, Frith U. 2012. Mechanisms of social cognition. *Annu Rev Psychol* 63:287–313.
- Glickstein M, Whitteridge D. 1987. Tatsuji Inouye and the mapping of the visual fields on the human cerebral cortex. *Trends Neurosci* 10(9):350–3.
- Gobbini MI, Gors JD, Halchenko YO, Hughes HC, Cipolli C. 2013. Processing of invisible social cues. *Conscious Cogn* 22(3):765–70.
- Goebel R, Muckli L, Zanella FE, Singer W, Stoerig P. 2001. Sustained extrastriate cortical activation without visual awareness revealed by fMRI studies of hemianopic patients. *Vision Res* 41(10–11):1459–74.
- Goodale MA, Milner AD. 1992. Separate visual pathways for perception and action. *Trends Neurosci* 15(1):20–5.
- Hall N, Colby C. 2014. S-cone visual stimuli activate superior colliculus neurons in old world monkeys: implications for understanding blindsight. *J Cogn Neurosci* 26(6):1234–56.
- Hendrickson AE, Wilson JR, Ogren MP. 1978. The neuroanatomical organization of pathways between the dorsal lateral geniculate nucleus and visual cortex in Old World and New World primates. *J Comp Neurol* 182(1):123–36.
- Hernandez-Gonzalez A, Cavada C, Reinoso-Suarez F. 1994. The lateral geniculate nucleus projects to the inferior temporal cortex in the macaque monkey. *Neuroreport* 5(18):2693–6.
- Hess RF, Pointer JS. 1989. Spatial and temporal contrast sensitivity in hemianopia. A comparative study of the sighted and blind hemifields. *Brain* 112(pt 4):871–94.
- Holmes G. 1918. Disturbances of vision by cerebral lesions. *Br J Ophthalmol* 2(7):353–84.
- Hubel DH, Wiesel TN. 1972. Laminar and columnar distribution of geniculo-cortical fibers in the macaque monkey. *J Comp Neurol* 146(4):421–50.
- Jayakumar J, Dreher B, Vidyasagar TR. 2013. Tracking blue cone signals in the primate brain. *Clin Exp Optom* 96(3):259–66.
- Jiang Y, He S. 2006. Cortical responses to invisible faces: dissociating subsystems for facial-information processing. *Curr Biol* 16(20):2023–9.
- Jiang Y, Shannon RW, Vizueta N, Bernat EM, Patrick CJ, He S. 2009. Dynamics of processing invisible faces in the brain: automatic neural encoding of facial expression information. *Neuroimage* 44(3):1171–7.
- Kaas JH, Lyon DC. 2007. Pulvinar contributions to the dorsal and ventral streams of visual processing in primates. *Brain Res Rev* 55(2):285–96.
- Kang MS, Blake R, Woodman GF. 2011. Semantic analysis does not occur in the absence of awareness induced by interocular suppression. *J Neurosci* 31(38):13535–45.
- Kanwisher N, McDermott J, Chun MM. 1997. The fusiform face area: a module in human extrastriate cortex specialized for face perception. *J Neurosci* 17(11):4302–11.



- Keshavan MS, Diwadkar VA, DeBellis M, Dick E, Kotwal R, Rosenberg DR, and others. 2002. Development of the corpus callosum in childhood, adolescence and early adulthood. *Life Sci* 70(16):1909–22.
- Leh SE, Johansen-Berg H, Ptito A. 2006. Unconscious vision: new insights into the neuronal correlate of blindsight using diffusion tractography. *Brain* 129(pt 7):1822–32.
- Liddell BJ, Brown KJ, Kemp AH, Barton MJ, Das P, Peduto A, et al. 2005. A direct brainstem-amygdala-cortical ‘alarm’ system for subliminal signals of fear. *Neuroimage* 24(1):235–43.
- Lin Z, He S. 2009. Seeing the invisible: the scope and limits of unconscious processing in binocular rivalry. *Prog Neurobiol* 87(4):195–211.
- Lister WT, Holmes G. 1916. Disturbances of vision from cerebral lesions, with special reference to the cortical representation of the macula. *Proc R Soc Med* 9(Sect Ophthalmol):57–96.
- Lyon DC, Nassi JJ, Callaway EM. 2010. A disynaptic relay from superior colliculus to dorsal stream visual cortex in macaque monkey. *Neuron* 65(2):270–9.
- Lysakowski A, Standage GP, Benevento LA. 1988. An investigation of collateral projections of the dorsal lateral geniculate nucleus and other subcortical structures to cortical areas V1 and V4 in the macaque monkey: a double label retrograde tracer study. *Exp Brain Res* 69(3):651–61.
- Marcel AJ. 1998. Blindsight and shape perception: deficit of visual consciousness or of visual function? *Brain* 121(pt 8):1565–88.
- Marks DF. 1973. Visual imagery differences in the recall of pictures. *Br J Psychol* 64(1):17–24.
- Masland RH. 2001. The fundamental plan of the retina. *Nat Neurosci* 4(9):877–86.
- Mendez-Bertolo C, Moratti S, Toledano R, Lopez-Sosa F, Martinez-Alvarez R, Mah YH, and others. 2016. A fast pathway for fear in human amygdala. *Nat Neurosci* 19(8):1041–9.
- Morland AB, Jones SR, Finlay AL, Deyzac D, Lê S, Kemp S. 1999. Visual perception of motion, luminance and colour in a human hemianope. *Brain* 122(pt 6):1183–98.
- Morland AB, Le S, Carroll E, Hoffmann MB, Pambakian A. 2004. The role of spared calcarine cortex and lateral occipital cortex in the responses of human hemianopes to visual motion. *J Cogn Neurosci* 16(2):204–18.
- Morris JS, DeGelder B, Weiskrantz L, Dolan RJ. 2001. Differential extrageniculostriate and amygdala responses to presentation of emotional faces in a cortically blind field. *Brain* 124(pt 6):1241–52.
- Morris JS, Frith CD, Perrett DI, Rowland D, Young AW, Calder AJ, and others. 1996. A differential neural response in the human amygdala to fearful and happy facial expressions. *Nature* 383(6603):812–5.
- Nelles G, Pscherer A, de Greiff A, Forsting M, Gerhard H, Esser J, et al. 2009. Eye-movement training-induced plasticity in patients with post-stroke hemianopia. *J Neurol* 256(5):726–33.
- Nelles G, Widman G, de Greiff A, Meistrowitz A, Dimitrova A, Weber J, et al. 2002. Brain representation of hemifield stimulation in poststroke visual field defects. *Stroke* 33(5):1286–93.
- O’Brien BJ, Abel PL, Olavarria JF. 2001. The retinal input to calbindin-D28k-defined subdivisions in macaque inferior pulvinar. *Neurosci Lett* 312(3):145–8.
- Pasik P, Pasik T, Schilder P. 1969. Extrageniculostriate vision in the monkey: discrimination of luminous flux-equated figures. *Exp Neurol* 24(3):421–37.
- Pasley BN, Mayes LC, Schultz RT. 2004. Subcortical discrimination of unperceived objects during binocular rivalry. *Neuron* 42(1):163–72.
- Pearson J, Naselaris T, Holmes EA, Kosslyn SM. 2015. Mental imagery: functional mechanisms and clinical applications. *Trends Cogn Sci* 19(10):590–602.
- Pegna AJ, Khatib A, Lazeyras F, Seghier ML. 2005. Discriminating emotional faces without primary visual cortices involves the right amygdala. *Nat Neurosci* 8:24–5.
- Perry VH, Cowey A. 1984. Retinal ganglion cells that project to the superior colliculus and pretectum in the macaque monkey. *Neuroscience* 12(4):1125–37.
- Pessoa L, Adolphs R. 2010. Emotion processing and the amygdala: from a ‘low road’ to ‘many roads’ of evaluating biological significance. *Nat Rev Neurosci* 11(11):773–83.
- Poppel E, Held R, Frost D. 1973. Residual visual function after brain wounds involving the central visual pathways in man. *Nature* 243(5405):295–6.
- Poppelreuter W. 1917. Die psychischen Schädigungen durch Kopfschuss im Kriege 1914–16; die Störungen der niederen und höheren Sehleistungen durch Verletzungen des Okzipitalhirns. Leipzig, Germany: Voss.
- Riddoch G. 1917. On the relative perceptions of movement and a stationary object in certain visual disturbances due to occipital injuries. *Proc R Soc Med* 10(Neurol Sect):13–34.
- Rizzo M, Robin DA. 1996. Bilateral effects of unilateral visual cortex lesions in human. *Brain* 119(pt 3):951–63.
- Ruderman L, Lamy D. 2012. Emotional context influences access of visual stimuli to anxious individuals’ awareness. *Conscious Cogn* 21(2):900–14.
- Schadow J, Dettler N, Paramei GV, Lenz D, Fründ I, Sabel BA, and others. 2009. Impairments of Gestalt perception in the intact hemifield of hemianopic patients are reflected in gamma-band EEG activity. *Neuropsychologia* 47(2):556–68.
- Schmid MC, Panagiotaropoulos T, Augath MA, Logothetis NK, Smirnakis SM. 2009. Visually driven activation in macaque areas V2 and V3 without input from the primary visual cortex. *PLoS One* 4(5):e5527.
- Schoenfeld MA, Noesselt T, Pöggel D, Tempelmann C, Hopf JM, Woldorff MG, and others. 2002. Analysis of pathways mediating preserved vision after striate cortex lesions. *Ann Neurol* 52(6):814–24.
- Sereno M, Allman J. 1991. Cortical visual areas in mammals. In: Leventhal A, editor. *The Neural Basis of Visual Function*. London: Macmillan. p. 160–72.
- Sheinberg D, Logothetis NK. 1997. The role of temporal cortical areas in perceptual organization. *Proc Natl Acad Sci U S A* 94:3408–13.
- Silvanto J, Cawey A, Lavie N, Walsh V. 2007. Making the blindsighted see. *Neuropsychologia* 45(14):3346–50.
- Sincich LC, Park KF, Wohlgenuth MJ, Horton JC. 2004. Bypassing V1: a direct geniculate input to area MT. *Nat Neurosci* 7(10):1123–8.



- Singhal A, Monaco S, Kaufman LD, Culham JC. 2013. Human fMRI reveals that delayed action re-recruits visual perception. *PLoS One* 8(9):e73629.
- Solca M, Guggisberg AG, Schnider A, Leemann B. 2015. Facial blindsight. *Front Hum Neurosci* 9:522.
- Stein T, Sterzer P. 2011. High-level face shape adaptation depends on visual awareness: evidence from continuous flash suppression. *J Vis* 11(8):5.
- Sterzer P, Haynes JD, Rees G. 2008. Fine-scale activity patterns in high-level visual areas encode the category of invisible objects. *J Vis* 8(15):1-12.
- Sterzer P, Jalkanen L, Rees G. 2009. Electromagnetic responses to invisible face stimuli during binocular suppression. *Neuroimage* 49(3):803-8.
- Stoerig P. 2006. Blindsight, conscious vision, and the role of primary visual cortex. *Prog Brain Res* 155:217-34.
- Stoerig P, Barth E. 2001. Low-level phenomenal vision despite unilateral destruction of primary visual cortex. *Conscious Cogn* 10(4):574-87.
- Tamietto M, Pullens P, de Gelder B, Weiskrantz L, Goebel R. 2012. Subcortical connections to human amygdala and changes following destruction of the visual cortex. *Curr Biol* 22(15):1449-55.
- Teuber H-L, Battersby WS, Bender MB. 1960. Visual field defects after penetrating missile wounds of the brain. Cambridge, MA: Harvard University Press.
- Tong F, Nakayama K, Vaughan JT, Kanwisher N. 1998. Binocular rivalry and visual awareness in human extrastriate cortex. *Neuron* 21(4):753-9.
- Tootell RB, Hamilton SL, Switkes E. 1988. Functional anatomy of macaque striate cortex. IV. Contrast and magno-parvo streams. *J Neurosci* 8(5):1594-609.
- Trevelyan CT, Sahaie A, Weiskrantz L. 2007. Form discrimination in a case of blindsight. *Neuropsychologia* 45(9):2092-103.
- Troiani V, Schultz RT. 2013. Amygdala, pulvinar, and inferior parietal cortex contribute to early processing of faces without awareness. *Front Hum Neurosci* 7:241.
- Tsuchiya N, Moradi F, Felsen C, Yamazaki M, Adolphs R. 2009. Intact rapid detection of fearful faces in the absence of the amygdala. *Nat Neurosci* 12:1224-5.
- Van den Stock J, Tamietto M, Sorger B, Pichon S, Grézes J, de Gelder B. 2011. Cortico-subcortical visual, somatosensory, and motor activations for perceiving dynamic whole-body emotional expressions with and without striate cortex (V1). *Proc Natl Acad Sci U S A* 108(39):16188-93.
- Van Essen DC, Newsome WT, Bixby JL. 1982. The pattern of interhemispheric connections and its relationship to extrastriate visual areas in the macaque monkey. *J Neurosci* 2(3):265-83.
- Warner CE, Goldshmit Y, Bourne JA. 2010. Retinal afferents synapse with relay cells targeting the middle temporal area in the pulvinar and lateral geniculate nuclei. *Front Neuroanat* 4:8.
- Warner CE, Kwan WC, Bourne JA. 2012. The early maturation of visual cortical area MT is dependent on input from the retinorecipient medial portion of the inferior pulvinar. *J Neurosci* 32(48):17073-85.
- Weber JT, Huerta MF, Kaas JH, Harting JK. 1983. The projections of the lateral geniculate nucleus of the squirrel monkey: studies of the interlaminar zones and the S layers. *J Comp Neurol* 213(2):135-45.
- Weiskrantz L. 1987. Residual vision in a scotoma. A follow-up study of 'form' discrimination. *Brain* 110(1):77-92.
- Weiskrantz L, Warrington EK, Sanders MD, Marshall J. 1974. Visual capacity in the hemianopic field following a restricted occipital ablation. *Brain* 97(4):709-28.
- Whitwell RL, Striemer CL, Nicolle DA, Goodale MA. 2011. Grasping the non-conscious: preserved grip scaling to unseen objects for immediate but not delayed grasping following a unilateral lesion to primary visual cortex. *Vision Res* 51(8):908-24.
- Williams MA, Morris AP, McGlone F, Abbott DF, Mattingley JB. 2004. Amygdala responses to fearful and happy facial expressions under conditions of binocular suppression. *J Neurosci* 24(12):2898-904.
- Wong-Riley MT. 1976. Projections from the dorsal lateral geniculate nucleus to prestriate cortex in the squirrel monkey as demonstrated by retrograde transport of horseradish peroxidase. *Brain Res* 109(3):595-600.
- Zeki S, Ffytche DH. 1998. The Riddoch syndrome: insights into the neurobiology of conscious vision. *Brain* 121 (pt 1):25-45.
- Zeman A, Dewar M, Della Sala S. 2015. Lives without imagery—congenital aphantasia. *Cortex* 73:378-80.
- Zhang X, Kedar S, Lynn MJ, Newman NJ, Biouesse V. 2006. Natural history of homonymous hemianopia. *Neurology* 66:901-5.